

FOREIGN BODY ON RIGHT LATERAL BORDER OF TONGUE THAT MIMICKS VARIX: A CASE REPORT

Tengku Natasha Eleena Tengku Ahmad Noor^{a*}, Amaradran Dass^b, Liana Ma Abdullah^c

^a Dental Officer of 609 Armed Forces Dental Clinic, Semenggo Camp, Kuching, Sarawak, Malaysia

^b Oral and Maxillofacial Surgeon of Oral and Maxillofacial Surgery Department, 94 Armed Forces Hospital, Terendak Camp, Melaka, Malaysia

^c Oral Medicine and Oral Pathology Specialist, Tuanku Mizan Armed Forces Hospital, Kuala Lumpur, Malaysia

ARTICLE INFO

ARTICLE HISTORY

Received: 11-05-2021

Received: 29-07-2021

Accepted: 21-09-2021

Published: 31-12-2021

KEYWORDS

Foreign

Bluish

Mass

Military

Amalgam

ABSTRACT

Foreign body impaction in the oral cavity either due to traumatic injury or iatrogenically is not uncommon. Most encountered iatrogenic foreign bodies is restorative materials such as amalgam, obturation materials, broken instruments and needles. Majority of foreign bodies are impacted in tonsils, base of tongue, maxillary sinus and vallecula. However, foreign bodies impaction in the mobile tongue is rare. We present a case of unusual foreign body impaction on the right lateral border of tongue appeared as bluish mass. A 40-year-old female military personnel came to Oral and Maxillofacial Surgery Department of 94-Armed Forces Hospital Terendak Camp complaining of bluish, painless mass on the right side of her tongue for 4 years. Excisional biopsy has been done and histopathological examination reveals foreign body impaction, likely amalgam tattoo. Amalgam tattoos can sometimes be confused with other foreign body pigmentations, being then biopsied. Once amalgam tattoos have been established, the removal of lesions is not necessary, except for esthetic reasons.

1.0 INTRODUCTION

Foreign bodies impact in the oral cavity is not well documented as it is usually asymptomatic and easily removed by the patients themselves [1]. These foreign bodies include food and non-food objects such as dental materials, toothpicks, wooden materials, pencil tips, straws, plastics, glass and other metals [1]. These objects may be impacted in the cavities of the broken or fractured teeth, gums, tongue, floor of the mouth, tonsillar fossa and the jaw bones [2-4]. Occasionally these objects may be found incidentally since they are asymptomatic. However, the diagnosis of these should be based on thorough clinical history and examination. Histopathological examination is compulsory for a definitive diagnosis.

An oral venous varix, or varicosity, is a common type of acquired vascular malformation [5]. According to World Health Organisation (WHO), varix is regarded as a physiological process and is categorized as a normal variation that is not hazardous to oral health [6]. According to Ettinger (1974), varix is an acquired benign lesion of vein, artery or lymphatic vessels that is abnormally dilated and tortuous. Varices of the ventral surface of the tongue is the most common oral finding [7-8]. We described a case of a 40-year-old female presented with bluish mass mimicking varix on the right lateral border of tongue.

2.0 CASE PRESENTATION

A 40-year-old female military personnel is referred to the Department of Oral and Maxillofacial Surgery, 94-Armed Forces Hospital, Terendak Camp in February 2019 with a complaint of persistent bluish mass on the right side of her tongue for 4 years (Figure 1). The patient claimed that the mass is painless but

gradually getting bigger in size. She defaulted on treatment 2 years ago after being advised to exercise mass.

Upon examination, the patient appears to be fit, has no underlying diseases and is not under any medications. She denied any systemic or infectious diseases. The pre-treatment photograph showed a single, smooth, and bluish coloured mass with the size of 3mm x 3mm on the mid right lateral border of the tongue (Figure 1). The lesion is not tender to palpation, not indurated and fluctuant. Blanching test was done and shows negative. Besides, there is no associated ulcer or lymphadenopathy found and, differential diagnosis of varix, melanotic macule and naevus are given. The patient wishes to have the lesion removed as it looks deformed and unsightly.

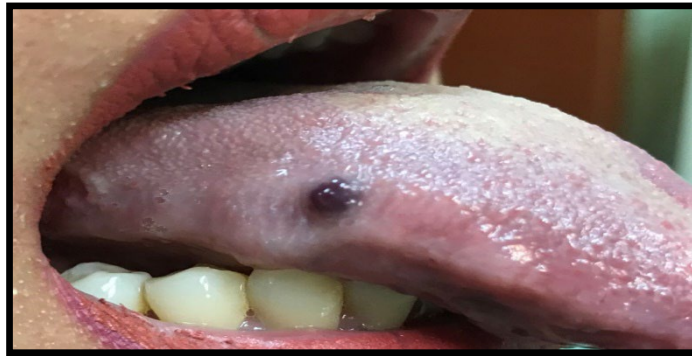

Figure 1. Pre-treatment photograph showing bluish black mass on the right lateral border of the tongue

Excisional biopsy of the bluish mass is performed under local anaesthesia by using laser to control the bleeding (Figure 2). The excised specimen is then sent to the laboratory for histopathological examination to get the definitive diagnosis of this case. A post-treatment photograph is taken (Figure 3) for record purposes and the patient is advised to avoid eating spicy food, avoid consuming hot drink and avoid smoking for 1 hour after the treatment.

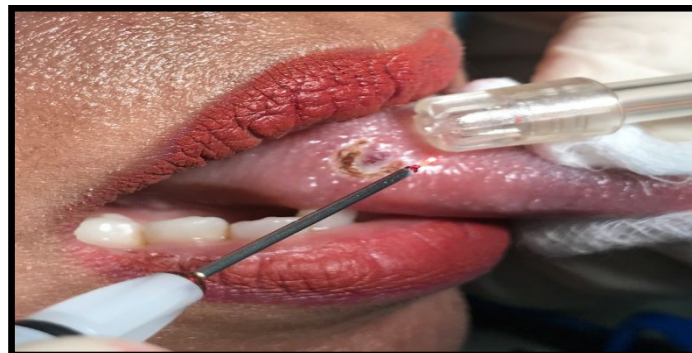

Figure 2. Laser is used to excise the mass

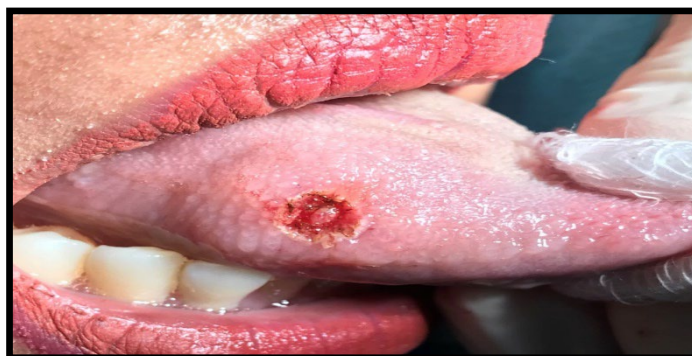

Figure 3. The tongue - after excision of the mass

Histopathological examination shows deposition of fine, irregular brownish black particles in the connective tissue adjacent to the epithelium (Figure 4a and 4b). No abnormal melanocytes or naevus cells

are found. Staining with Fontana-Masson is negative. The appearance is consistent with foreign body tattoos. In view of the presence of amalgam restorations in the adjacent teeth (Figure 5), it is most likely an amalgam tattoo. A review after one month of excision shows that the healing is monotonous, and the patient is satisfied with the treatment performed (Figure 6).

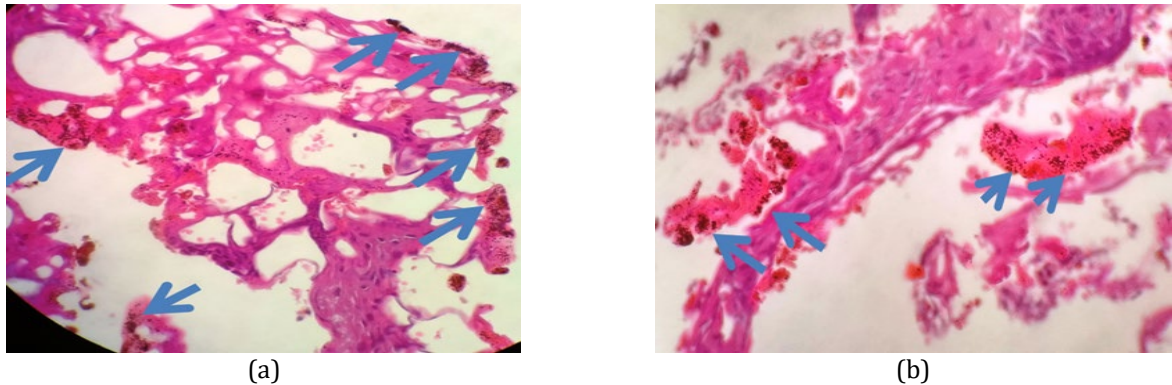


Figure 4a and 4b: Slides of excised mass at 10x and 40x magnification respectively

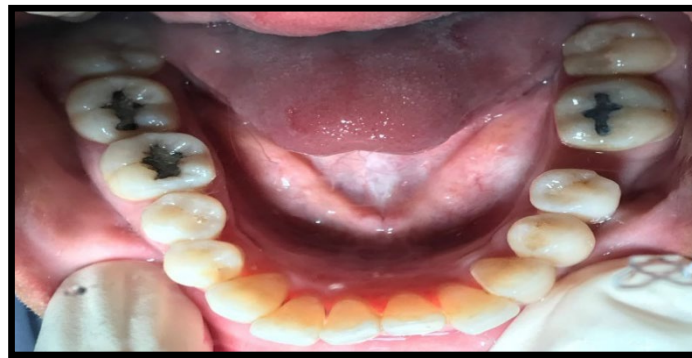

Figure 5. Presence of amalgam filling on adjacent teeth

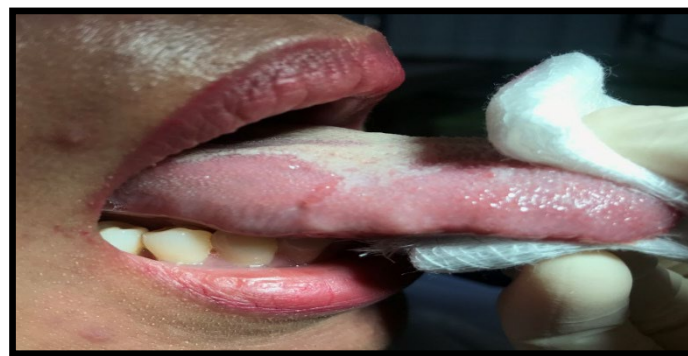

Figure 6. Signs of healing after at 1 month review

3.0 DISCUSSION

Amalgam tattoo or amalgam pigmentation is the most common acquired pigmented lesion on the oral mucosa [9]. Amalgam is the most used dental restorative material for dental fillings as it is relatively easy to pack and inexpensive. It is an alloy of liquid mercury with varying amounts of silver, tin, copper and zinc. Amalgam tattoos can be caused by amalgam splinters inadvertently implanted into the mucosa while restoring the tooth but may also cause by diffusion through the teeth [9-10]. Clinically it presents as grey, blue or black, non-blanching macules in the oral mucosa typically seen on the gingiva, alveolar, buccal mucosa or floor of the mouth [11]. Their appearance can be difficult to discern from other pigmented elements of the oral mucosa including mucosal varix.

Histologically, deposits of amalgam are seen as granules along blood vessels and collagen fibres or as solid fragments in the tissue [12]. In this case irregular brownish black particles in the connective tissue

adjacent to the epithelium are consistent with foreign body tattoo. Amalgam tattoos are harmless and asymptomatic [13]. They can be safely diagnosed by the finding of radio-opaque granules on x-ray or with histopathology [11-12, 14]. However, these particles are often too small or too widely dispersed to be visible on X-rays, thus negative radiographic findings cannot rule out amalgam tattoo [15].

Generally, removal of amalgam tattoos is not necessary except for cosmetic reasons. If the pigmentation is unacceptable, surgical excision has been suggested. Q-switched ruby laser and Q-switched alexandrite laser have been used with favourable results [16]. In this case, laser is used to remove the pigmented mass as requested by the patient. However, by using laser, it can affect the histopathological appearance of lesion, hence not encouraged.

4.0 CONCLUSION

In conclusion, we report a case of an amalgam tattoo that caused oral pigmentation that resembles varix. Amalgam tattoo is difficult to be differentiated from another pigmented lesion clinically. Thus, removal followed by histological confirmation is necessary.

5.0 ACKNOWLEDGEMENT

Dental Service of Malaysian Armed Forces and Ethical Board of Tuanku Mizan Armed Forces Hospital

List of Reference

- [1] Ajike, S. O. (2015). Impacted foreign bodies in Dentistry. *Journal of the West African College of Surgeons*, 5(3), x.
- [2] Lamster, I. B., & Barenie, J. T. (1977). Foreign objects in the root canal: Review of the literature and report of two cases. *Oral Surgery, Oral Medicine, Oral Pathology*, 44(3), 483-486.
- [3] Al-Muharraqi, M. A. (2010). Unusual Foreign Object in the Palate of an Infant—More Fingernails!. *Journal of Oral and Maxillofacial Surgery*, 68(7), 1701-1702.
- [4] Tavargeri, A. K., Rao, C. B., & Thakur, S. (2010). Foreign body in the mouth and the dilemma in diagnosis: a case report. *Journal of the California Dental Association*, 38(7), 512-513.
- [5] Partridge, L. (2010). The new biology of ageing. *Philosophical Transactions of the Royal Society B: Biological Sciences*, 365(1537), 147-154.
- [6] Kramer, I. R., Pindborg, J. J., Bezroukov, V., & Infirri, J. S. (1980). Guide to epidemiology and diagnosis of oral mucosal diseases and conditions. World Health Organization. *Community dentistry and oral epidemiology*, 8(1), 1-26.
- [7] Ettinger, R. L., & Manderson, R. D. (1974). A clinical study of sublingual varices. *Oral Surgery, Oral Medicine, Oral Pathology*, 38(4), 540-545.
- [8] Pemberton, M. N. (2006). Sublingual varices are not unusual. *BMJ*, 333(7560), 202.
- [9] Buchner, A., & Hansen, L. S. (1980). Amalgam pigmentation (amalgam tattoo) of the oral mucosa: a clinicopathologic study of 268 cases. *Oral Surgery, Oral Medicine, Oral Pathology*, 49(2), 139-147.
- [10] Owens, B. M., Johnson, W. W., & Schuman, N. J. (1992). Oral amalgam pigmentations (tattoos): a retrospective study. *Quintessence international*, 23(12).
- [11] Eisen, D. (2000). Disorders of pigmentation in the oral cavity. *Clinics in dermatology*, 18(5), 579-587.
- [12] Krahl, D., Altenburg, A., & Zouboulis, C. C. (2008). Reactive hyperplasias, precancerous and malignant lesions of the oral mucosa. *JDDG: Journal der Deutschen Dermatologischen Gesellschaft*, 6(3), 217-232.
- [13] Lundin, K., Schmidt, G., & Bonde, C. (2013). Amalgam tattoo mimicking mucosal melanoma: a diagnostic dilemma revisited. *Case Reports in Dentistry*, 2013(1), 787294.
- [14] Adel Kauzman, B. D. S., Pavone, M., Blanas, N., & Bradley, G. (2004). Pigmented lesions of the oral cavity: review, differential diagnosis, and case presentations. *J Can Dent Assoc*, 70(10), 682-3.
- [15] Amano, H., Tamura, A., Yasuda, M., Yamanaka, M., Takeuchi, Y., Sasaoka, K., ... & Ishikawa, O. (2011). Amalgam tattoo of the oral mucosa mimics malignant melanoma. *The Journal of Dermatology*, 38(1), 101-103.
- [16] Ashinoff, R., & Tanenbaum, D. (1994). Treatment of an amalgam tattoo with the Q-switched ruby laser. *Cutis*, 54(4), 269-270.